

## Distemper: Not a New Disease in Lions and Tigers

DENISE L. MYERS,<sup>1\*</sup> ANDREAS ZURBRIGGEN,<sup>2</sup> HANS LUTZ,<sup>3</sup> AND ANDREAS POSPISCHIL<sup>1</sup>

*Department of Veterinary Pathology<sup>1</sup> and Department of Veterinary Internal Medicine,<sup>3</sup> University of Zurich, CH-8057 Zurich, and Institute for Animal Neurology, University of Bern, CH-3012 Bern,<sup>2</sup> Switzerland*

Received 30 August 1996/Returned for modification 30 September 1996/Accepted 19 November 1996

**In light of recent canine distemper virus (CDV) epidemics, we set out to determine the historical significance of CDV infection in captive lions and tigers in Switzerland. The retrospective case material consisted of 42 lion and tiger necropsy cases from 1972 to 1992. Necropsy reports for all lions and tigers were reviewed. All existing paraffin tissues were immunohistochemically examined with a polyclonal antibody raised against CDV. The results for 19 of the 42 lions and tigers were classified as positive by immunohistochemistry; 23 results were negative or questionable. The results for four animals (three positive and one negative) were further tested by in situ hybridization, and the results concurred with the immunohistochemistry findings. CDV infection of large cats is older and more widespread than previously thought. All large cats in captivity should be immunized even if canine distemper is not believed to be a problem for large cats in the area.**

Canine distemper virus (CDV) is a negative-stranded morbillivirus of the *Paramyxoviridae* family. In the last few years, novel CDV and related morbillivirus infections have occurred worldwide in large cats (4, 23) hyenas (1, 14), various marine mammals (6–11, 15, 18), and horses and humans (19). In large cats, two recent canine distemper epidemics have been reported: one in California (4) and the other in the Serengeti (23). Both were characterized by significant fatality rates, 23 and 30%, respectively.

In current reports on large-cat distemper, one repeatedly finds that CDV historically is not pathogenic in lions and tigers (3, 5, 23) and that there are few previous reports of CDV in exotic felids (4, 5, 26). We have uncovered evidence that questions both these tenets and affects our basic understanding of the disease.

While looking for an immunohistochemistry-negative control for CDV-infected lion tissues, we were surprised to find positively labeled CDV antigen in material from captive lions in Switzerland. We then set out to determine the historical incidence of CDV infection in captive lions and tigers in Switzerland. Archival formalin-fixed, paraffin-embedded tissue was sought from routine case material at the Department of Veterinary Pathology of the University of Zurich. We were able to retrieve 42 necropsy cases from 1972 to 1992; 18 cases originated from the Zurich Zoo, and the rest were from various small circuses and zoos in Switzerland. Case histories and necropsy reports were also retrieved for these animals. None of the animals had been immunized against CDV.

(This work was carried out by D. Myers as part of a dissertation under the direction of A. Pospischil and H. Lutz.)

### MATERIALS AND METHODS

**Immunohistochemistry.** One to 19 slides per animal from diverse organs were examined. Each section was incubated with a rabbit polyclonal antibody specifically raised against CDV antigen (courtesy of D. Palmer, Animal Health Laboratories, South Perth, Australia). In brief, sections were deparaffinized, rehydrated, digested for 5 min with 0.1% protease (protease type XXVII (P 7489); Sigma Chemical Company), peroxidase blocked, covered with normal swine serum (Universal peroxidase antiperoxidase reaction [PAP] kits; DAKO Diagnostics) for 10 min, and incubated with the polyclonal antibody at a concentra-

tion of 1:200 overnight at room temperature. They were then incubated with swine anti-rabbit immunoglobulin G (universal DAKO PAP kits) for 20 min at room temperature and visualized by the PAP. Finally, samples were counterstained with hemalaun (according to Mayer [14a]) for 10 s (21, 24).

A negative control with normal rabbit antibody (universal DAKO PAP kits) was made per slide. A positive control from the cerebellum of a canine spontaneously infected with distemper was run for each batch of slides. During slide examination, the examiner was blind to each animal's identity.

**In situ hybridization.** Slides for four animals were then examined in situ hybridization with a probe specific for CDV mRNA according to Zurbriggen et al. (27). Briefly, the deparaffinized sections were rehydrated, washed with phosphate-buffered saline (PBS), and treated for 10 min with 0.2 M HCl. The samples were incubated with proteinase K (Boehringer Mannheim) at a concentration of 1 µg/ml of 20 mM Tris-HCl (pH 7.5)–2 mM CaCl<sub>2</sub> for 20 min at 37°C. After treatment, samples were further fixed with 4% paraformaldehyde in PBS, followed by the addition of 0.2% glycine in PBS, and washed again with PBS. Slides were then prehybridized at 52°C for 1 h in 50% formamide–5× SSC (1× SSC is 0.15 M NaCl plus 0.015 M sodium citrate)–5× Denhardt's reagent (Sigma Chemical Company)–500 µg of salmon sperm DNA (Sigma)/ml. The sections were hybridized at 52°C overnight in 50% formamide–10× dextran sulfate–5× hybridization salts (Merck and Sigma Chemical Company)–20 U of heparin/ml–0.1% Triton X-100 (Merck)–10% dextran sulfate–500 µg of denatured salmon sperm DNA/ml–approximately 10 ng of digoxigenin-labeled RNA probe/100 µl. After hybridization, excess labeled RNA was removed by several washes with SSC and treatment with RNase (Boehringer Mannheim). The slides were then incubated with an antidigoxigenin antibody conjugated with phosphatase, followed by development in nitroblue tetrazolium and X-phosphate (Sigma) (27). Slides were examined by differential interference contrast microscopy. The experimenter was unaware of the immunohistochemistry results.

### RESULTS

On the basis of immunohistochemistry examination, the result for the 42 lions and tigers were classified as follows: 19, positive; 15, negative; and 8, questionable (Table 1). Both intracytoplasmatic and intranuclear labeling was seen in most CDV-positive tissues (Fig. 1). The first CDV-positive case was from 1972. The animals ranged in age from neonatal to 17 years. Ten animals originated from seven various small zoos and circuses, with no apparent clustering of animals from a particular facility or in a particular year. The other nine animals were from the Zurich Zoo. Of the lions and tigers with positive results, 63% exhibited neurological symptoms such as seizures, tonic-clonic contractions, falling, inability to rise, and paresis (Four of the animals with negative or questionable results, or 17%, exhibited neurologic symptoms; three of these four were found to have severe radiological changes which could account for the symptoms.), 42% showed anorexia, 26% had digestive disorders, 5% had respiratory symptoms; and 37% had a concurrent illness: parvovirus infection (two ani-

\* Corresponding author. Mailing address: Department of Veterinary Pathology, University of Zurich, Winterthurerstr. 268, CH-8057 Zurich, Switzerland. Phone: 41 1 635 85 51. Fax: 41 1 635 89 08. E-mail: apos@vetpath.unizh.ch.

TABLE 1. Descriptions of immunohistochemically CDV-positive lions and tigers

Animal (gender)	Age	Yr of sampling	Origin <sup>a</sup>	Clinical sign(s)	Source of tissue with CDV-positive result by:	
					PAP	In situ hybridization
Lion (F)	2 yr	1972	P1	Anorexia, seizures, tonic clonic cramps, digestive signs	Lymph node intestine, spinal cord, brain	Spinal cord, brain
Tiger (M)	8 yr	1977	ZH	Yearly seizures, anorexia	Lung, spleen, kidney, intestine, testes	
Lion (F)	10 mo	1977	P2	Somnolence, inappetence, anorexia	Intestine	
Lion (M)	16 yr	1977	ZH	Automutilation	Lung, kidney, brain	
Tiger (M)	2 yr	1979	P3	Tonic-clonic cramps	Stomach, spinal cord, brain	
Lion (M)	Adult	1981	P4	Inability to rise, moribund	Lung	
Lion (M)	Neonate	1981	ZH	Neonatal death	Lung	
Tiger (M)	13 yr	1986	P4	Anorexia, fell from stand, moribund	Brain, spinal cord, kidney	
Lion (F)	9 yr	1986	ZH	Tumor	Lymph node	
Tiger (M)	6 yr	1987	P5	Anorexia, diarrhea	Intestine, lung	
Lion (M)	14 mo	1987	P1	Sudden death	Lymph node intestine, lung, brain, thyroid, adrenal	
Lion (F)	3 mo	1988	P6	Sudden paresis of hind legs, hypersensitivity	Lung	Lung
Tiger (F)	14 yr	1989	ZH	Somnolence, weaves on hind legs, anorexia, black feces	Lung, spleen	
Lion (F)	Adult	1989	ZH	Peritonitis	Spleen, heart, glandular tissue, peritoneum	
Tiger (F)	14 yr	1990	P7	Progressive ataxia (front), anorexia, cramp-like stiffness	Brain, tongue, urinary bladder	
Lion (M)	13 yr	1991	ZH	Stiff gait (hind), difficulty moving, round back, pain	Spinal cord	
Lion (F)	13 yr	1991	P2	Dyspnea, coughing, nasal discharge, anorexia	Lung, lymph node	Lung
Lion (M)	5 yr	1991	ZH	Lentivirus positive (euthanized)	Spleen	
Tiger (M)	17 yr	1992	ZH	Bouts of weakness each fall, anorexia	Bladder	

<sup>a</sup> P, private zoo or circus (numbered 1 through 7); ZH, Zurich Zoo.

mals) tuberculosis, osteodystrophia fibrosa, arthritis, stomach ulcer, or fibrosarcoma.

At the time of autopsy, a variety of histologic changes were seen in the lions and tigers with positive results. The brain changes in hematoxylin- and eosin-stained sections were uni-

formly subtle. A mild nonsuppurative meningoencephalitis with a predilection for the hippocampal region, as well as neuronal degeneration, particularly of the white matter, diffuse gliosis, and infrequent, mild perivascular lymphoplasmacytic cuffing were noted. A review of brain slides also revealed a few

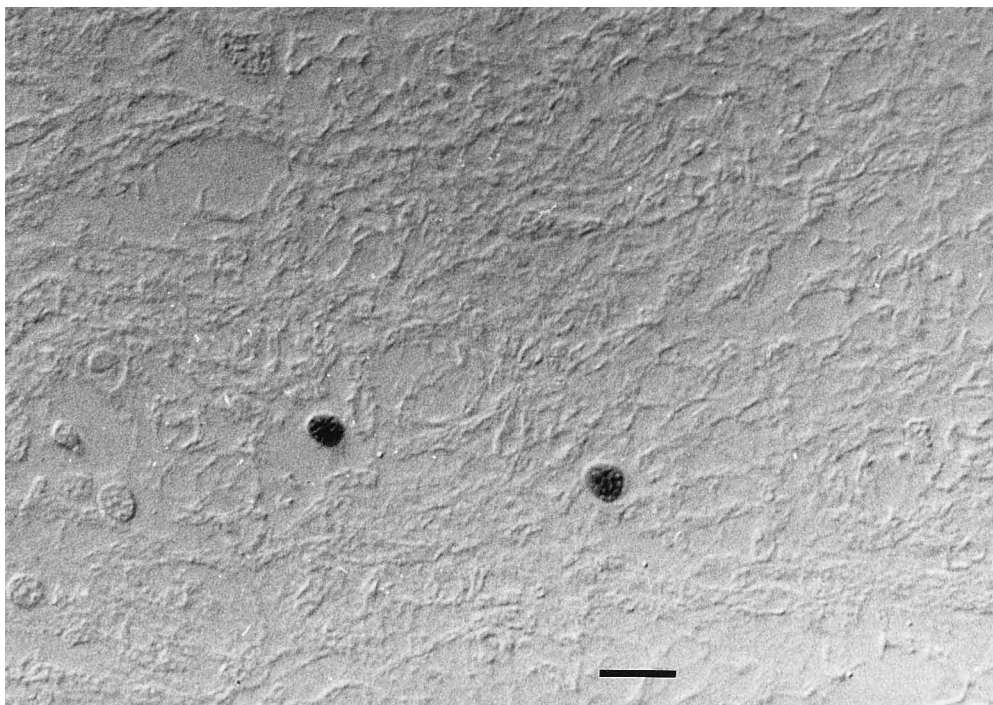


FIG. 1. Polyclonal PAP without contrast stain of cerebral cortex tissue from a tiger, demonstrating intranuclear labeling. Bar, 26.3  $\mu$ m.

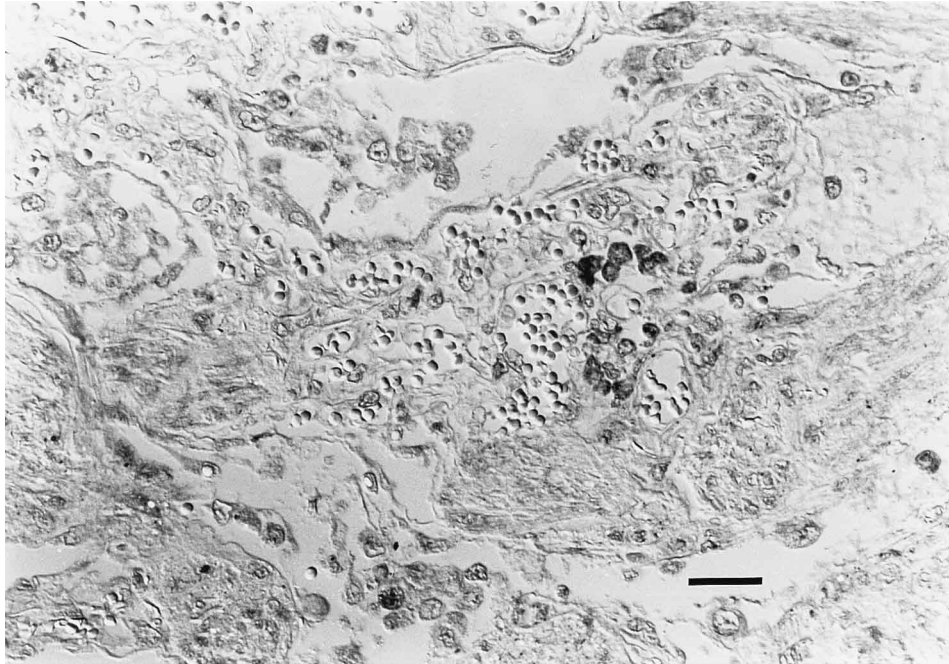


FIG. 2. In situ hybridization demonstrating CDV mRNA in single cells of lion lung tissue. Bar, 50  $\mu$ m.

eosinophilic intranuclear and intracytoplasmic inclusion bodies. Lung changes were also seen in the large cats with positive results; severe chronic active interstitial pneumonia, and purulent bronchitis were described. Diverse enteritic changes were observed: chronic enteritis with granuloma formation, severe acute diphtheroid enteritis, and diffuse nonpurulent intestinal infiltrates.

For the one negative and three positive cases examined, the in situ hybridization results were in concordance with the immunohistochemistry findings (Fig. 2).

Three Zurich Zoo lions with positive results, the only animals tested, were feline immunodeficiency virus (FIV) positive by enzyme-linked immunosorbent assay and Western blotting techniques (17). One of these lions was euthanized due to the FIV result alone and was the only animal in the study to be euthanized in a clinically healthy state. The rest of the large cats in the study were either euthanized due to poor prognosis or died.

## DISCUSSION

From our immunohistochemical results, in situ hybridization, histology, necropsy reports, and similarities of these findings to those reported in the literature for large-cat distemper cases, we believe that lions and tigers have been infected with CDV for at least 24 years and that distemper could have been a significant factor in lion and tiger mortality. We also speculate that the CDV incidence in our case material could have been even higher than that found since a suitable palette of tissue samples was not available from each lion and tiger. In particular, since the skulls of exotic felids are highly valued for museum preparation, brain tissue is sometimes not submitted for necropsy. On the other hand, our case material could also be skewed with regard to distemper cases, since owners are more likely to request necropsies for animals with severe and baffling symptoms. Therefore, the surprisingly high incidence

of distemper that we identified could be inflated with regard to the general population.

In any case, our findings indicate that CDV in large cats is considerably older and more widespread than previously thought. The few existing clinical reports of suspected or demonstrated nondomestic felid CDV disease in Africa in 1950 (22), in the United States in 1983 (5, 13) and 1989 (12), and in Canada in 1995 (26) suggest that our findings in Switzerland may not be a unique phenomenon. Interestingly, German literature from 1910 (15) and 1931 (25) states that both domestic cats and leopards are able to contract canine distemper but do so infrequently.

One noteworthy aspect of our cases, especially with regard to the recently published epidemics, is that usually only individuals were affected. We did not observe multiple cases of CDV-positive large cats originating at the same time from the same institution, except for the three FIV-positive lions from the Zurich Zoo, discussed separately below. Also, in cases where we were able to find information on cage mates, they displayed no symptoms and therefore were not necropsied. The possibility does exist that CDV disease was infrequently transmitted but the other affected animals were not submitted for necropsy.

An exception to this general trend is the FIV-positive Zurich lions. Three lions, a 9-year-old female, her 13-year-old mate, and their 5-year-old son (and only offspring), all tested positive for FIV (17). All three lions were also immunohistochemically positive for CDV. The female was euthanized due to an inoperable fibrosarcoma, the male was euthanized due to a stiff hind gait of a few days duration that progressed to an inability to move, and their son was euthanized in a clinically healthy state. It is possible that these cats infected one another and that their immune status was altered through the FIV infection to allow this transfer. However, FIV positivity does not explain the California and Serengeti epidemics: only one CDV-diseased California animal was FIV positive, and no difference in

FIV status was observed in the CDV-diseased and nondiseased Serengeti populations.

Since at least the majority of the lions and tigers were not transmitting overt disease to one another, the question arises as to the source of disease. One of our CDV-positive lions was a cub that had been hand raised with direct canine contact, although we have no information as to the health status of these dogs. This mode of infection theoretically exists; in the case from Africa (22), two cubs died of apparent CDV disease after contact with a dog displaying classic distemper symptoms. Dog contact was also documented for the tiger described by Blyth et al. (5). However, it seems more likely that the majority of our cases were transmitted through distemper-infected wild animals such as, for example, martins, which have been demonstrated to harbor the disease in Switzerland (20). In zoos and circuses, it is difficult to eliminate such contact, since indigenous wildlife is always attracted to food-rich enclosures.

The puzzle as to why some lions and tigers contract canine distemper while their neighbors usually do not remains unsolved. One explanation could be that the exotic felids do not shed appreciable amounts of virus and require extensive contact with another species of distemper-infected animal, and therefore a high viral infectious dose, to contract disease; i.e., only the lion who eats the martin will contract disease. Another compatible possibility is that CDV infection in large cats requires as-yet-unknown predisposing factors, such as concurrent illness or immune suppression, to be pathogenic for large cats. This possibility could lead to one animal being clinically infected while its neighbor resists infection or has a clinically inapparent infection. Such silent infections in large cats were reported by Appel et al. (4) and have also been described in domestic cats (2). However, on the basis of comparing a range of viral antibody titers in affected and unaffected lions in the Serengeti, concurrent viral disease was not associated with an increase in CDV susceptibility. A problem with this approach is that the immunosuppressive nature of CDV infection could also affect antibody titer levels. The predisposing factors could be a combination of diseases or of diseases and environmental factors.

Another intriguing aspect of our findings was that two of our CDV-positive animals exhibited a protracted course of disease, with seizures occurring approximately once a year over several years. One other chronic case was previously reported, a tiger with a 1-year interlude between neurological symptoms (5). The other CDV-positive animals had a course of disease from a few days to 1.5 months, similar to descriptions of other large cat cases.

We are still left with the riddle as to why distemper in nondomestic felids sometimes affects individuals and rarely causes epidemics. Perhaps the individual cases result from one-on-one exposure to a diseased animal, possibly requiring additional factors, as postulated above. It could be that these self-limiting infections occasionally undergo a change in biotype within their host, resulting in a virus with dramatically increased large cat pathogenicity. Once this new biotype has spread through the population, surviving animals are immune to further infection, until a naive population exists, and factors combine once again to form another pathogenic biotype. The historical serology results presented from the Serengeti are not incompatible with this scenario. A more banal explanation is that there is no novel biotype and that captive exotic cats are held in groups too small to usually support an epidemic. However, the fact that CDV epidemics occur regularly in other animal species in the Serengeti but lion epidemics have never before been observed, despite long-term careful observation (23), makes this possibility highly unlikely.

In an interesting parallel, CDV infection of hyenas during a sympatric domestic and wild canid epidemic in the Masai Mara region elicited seroconversion but no symptoms (1). Infected hyenas also did not transmit virus horizontally within the same clan. In addition, new information published since the epidemic among Serengeti lions documents CDV infection resulting in increased sympatric hyena cub mortality (14). The isolated virus exhibited a >99% homology with the lion strain and was less closely related to domestic dog CDV. Reports of CDV causing mortality in captive hyenas also exist (1).

In addition to looking at CDV as a cause of large-cat epidemics, it will now be imperative, in light of recent dynamic, widespread morbillivirus infections, to turn to a global view and examine possible viral changes over time and the prevalence of CDV in all wild canid, felid, and other animal populations. Only then will we be able to understand larger issues of CDV pathogenesis and epidemiology and to identify and protect animal populations at risk. The broad and apparently expanding host range of distemper and related morbillivirus infections, as well as the realized zoonotic potential, underscores the importance of this knowledge.

#### ACKNOWLEDGMENTS

We gratefully acknowledge support from The Messerli Foundation; Graf Fabrice, von Grundlach, and the Payne Smith Foundation; and the Swiss Baking Corporation, on behalf of a customer.

We also thank Sabina Wunderlin, Rosaline Weilenmann, and Karin Beck for excellent technical assistance.

#### REFERENCES

- Alexander, K. A., P. W. Kat, L. G. Frank, K. E. Holekamp, L. Smale, C. House, and M. J. G. Appel. 1995. Evidence of canine distemper virus infection among free ranging spotted hyenas (*Crocuta crocuta*) in the Masai Mara, Kenya. *J. Zoo Wildl. Med.* **26**:201-206.
- Appel, M. J. G., B. E. Shelly, D. H. Percy, and J. A. Gaskin. 1974. Canine distemper virus in domesticated cats and pigs. *Am. J. Vet. Res.* **35**:803-806.
- Appel, M. J. G. 1987. Canine distemper virus, p. 133-159. *In* M. J. G. Appel (ed.), *Virus infections of carnivores*. Elsevier Science Publishers B.V., Amsterdam, The Netherlands.
- Appel, M. G. J., R. A. Yates, G. L. Foley, J. J. Bernstein, S. Santinelli, L. H. Spelman, L. D. Miller, L. H. Arp, M. Anderson, M. Barr, S. Pearce-Kelling, and B. A. Summers. 1994. Canine distemper epizootic in lions, tigers, and leopards in North America. *J. Vet. Diagn. Invest.* **6**:277-288.
- Blyth, L. L., J. A. Schmitz, M. Roelke, and S. Skinner. 1983. Chronic encephalomyelitis caused by canine distemper virus in a Bengal tiger. *J. Am. Vet. Med. Assoc.* **183**:1159-1162.
- Cebrian, D. 1995. The striped dolphin (*Stenella coeruleoalba*) epizootic in Greece, 1991-1992. *Biol. Conserv.* **74**:143-145.
- Di Guardo, G., U. Agrimi, L. Morelli, G. Cardetti, G. Terracciano, and S. Kennedy. 1995. Post mortem investigations on cetaceans found stranded on the coasts of Italy between 1990 and 1993. *Vet. Rec.* **136**:439-442.
- Domingo, M., L. Ferrer, M. Pumarola, A. Marco, J. Plana, S. Kennedy, M. McAliskey, and B. K. Rima. 1990. Epizootiology in dolphins. *Nature* **348**:21.
- Duigan, P. J., C. House, J. R. Geraci, G. Early, H. G. Copland, M. T. Walsh, G. D. Bossart, C. Cray, S. Sadove, D. J. St. Aubin, and M. Moore. 1995. Morbillivirus infection in two species of pilot whales (*Globicephala* sp.) from the Western Atlantic. *Mar. Mamm. Sci.* **11**:150-162.
- Duigan, P. J., C. House, M. T. Walsh, G. D. Bossart, N. Duffy, P. J. Fernandes, B. K. Rima, S. Wright, and J. R. Geraci. 1995. Morbillivirus infection in manatees. *Mar. Mamm. Sci.* **11**:441-451.
- Duigan, P. J., J. T. Saliki, D. J. St. Aubin, G. Early, S. Sadove, J. A. House, K. Kovacs, and J. R. Geraci. 1995. Epizootiology of morbillivirus infection in North American harbor seals (*Phoca vitulina*) and gray seals (*Halichoerus grypus*). *J. Wildl. Dis.* **31**:491-501.
- Fix, A. S., D. P. Riordan, and H. T. Hill. 1989. Feline panleukopenia and subsequent canine distemper virus infection in two snow leopards. *J. Zoo Wildl. Med.* **20**:273-281.
- Gould, D. H., and W. R. Fenner. 1983. Paramyxovirus-like nucleocapsids associated with encephalitis in a captive Siberian tiger. *J. Am. Vet. Med. Assoc.* **183**:1319-1322.
- Haas, L., H. Hofer, M. East, P. Wohlsein, B. Leiss, and T. Barrett. 1996. Canine distemper virus infection in Serengeti spotted hyenas. *Vet. Microbiol.* **48**:147-152.
- Hagemann, P., and K. Rosenmund. 1989. *Histotechnik*, p. 63. S. Hirzel Verlag, Stuttgart, Germany.

15. **Hutya, F., and J. Marek (ed.)**, 1910. *Spezielle Pathologie und Therapie der Haustiere*, p. 198–210. Jena Verlag von Gustav Fischer, Jena, Germany.
16. **Kraft, A., J. H. Lichy, T. P. Lipscomb, B. A. Klaunberg, S. Kennedy, and J. K. Taubenberger**. 1995. Postmortem diagnosis of morbillivirus infection in bottlenose dolphins (*Tursiops truncatus*) in the Atlantic and Gulf of Mexico epizootics by polymerase chain reaction-based assay. *J. Wildl. Dis.* **21**:410–415.
17. **Lutz, H., E. Isenbügel, R. Lehmann, R. H. Sabapara, and C. Wolfensberger**. 1992. Retrovirus infections in non-domestic felids: serological studies and attempts to isolate a lentivirus. *Vet. Immunol. Immunopathol.* **35**:215–224.
18. **Mamaev, L. V., I. K. G. Visser, S. I. Belikov, N. N. Denikina, T. Harder, L. Goatley, B. Rima, B. Edgington, A. D. M. E. Osterhaus, and T. Barrett**. 1996. Canine distemper virus in Lake Baikal seals (*Phoca siberica*). *Vet. Rec.* **138**:437–439.
19. **Murray, K., P. Selleck, P. Hooper, A. Hyatt, A. Gould, L. Gleeson, H. Westbury, L. Hiley, L. Selvey, B. Rodwell, and P. Ketterer**. 1995. A morbillivirus that caused fatal disease in horses and humans. *Science* **268**:94–97.
20. **Palmer, D., P. Ossent, A. Waldvogel, and R. Weilenmann**. 1983. Staupe-Encephalitis beim Steinmarder (*Martes foina*, Erleben, 1777) in der Schweiz. *Schweiz. Arch. Tierheilkd.* **125**:529–536.
21. **Palmer, D., C. Huxtable, and J. Thomas**. 1990. Immunohistochemical demonstration of canine distemper virus antigen as an aid in the diagnosis of canine distemper encephalomyelitis. *Res. Vet. Sci.* **49**:177–181.
22. **Piat, B. L.** 1950. Maladie de Carre chez deux lionceaux. *Bull. Serv Elevage Ind. Anim. Afr. Occident.* **3**:39–40.
23. **Roelke-Parker, M. E., L. Munson, C. Packer, R. Kock, S. Cleaveland, M. Carpenter, S. J. O'Brien, A. Pospischil, R. Hofmann-Lehmann, H. Lutz, G. L. M. Mwamengele, M. N. Mgasa, G. A. Machange, B. A. Summers, and M. J. G. Appel**. 1996. A canine distemper virus epidemic in East African lions (*Panthera leo*). *Nature* **379**:441–445.
24. **Vandevelde, M., A. Zurbriggen, R. Higgins, and D. Palmer**. 1985. Spread and distribution of viral antigen in nervous canine distemper. *Acta Neuropathol.* **67**:211–218.
25. **Wirth, D.** 1931. Staupe, p. 604–614. *In* V. Strang and D. Wirth (ed.), *Tierheilkunde und Tierzucht. Urban und Schwarzberg*, Berlin, Germany.
26. **Wood, S. L., G. W. Thomson, and D. M. Haines**. 1995. Canine distemper virus-like infection in a captive African lioness. *Can. Vet. J.* **36**:34–35.
27. **Zurbriggen, A., C. Müller, and M. Vandevelde**. 1993. In situ hybridization of virulent canine distemper virus in brain tissue, using digoxigenin-labeled probes. *Am. J. Vet. Res.* **54**:1457–1461.